















**Paciente:** DALI - 13575, Perro, SHITZU, 5 Year(s) 7 Month(s), Macho intacto

**Dueño:** AMPARO CALERO

**Veterinario solicitante:** Ninguno

**VETSCAN HM5c - Hematology**

Análisis	22/10/25 12:30 PM HM5	Intervalo de referencia	Gráfico
WBC	<b>7.36</b> 10 <sup>9</sup> /l	6 - 17	
LYM	<b>3.07</b> 10 <sup>9</sup> /l	1 - 4.8	
MON	<b>0.65</b> 10 <sup>9</sup> /l	0.2 - 1.5	
NEU	<b>3.42</b> 10 <sup>9</sup> /l	3 - 12	
EOS	<b>0.16</b> 10 <sup>9</sup> /l	0 - 0.8	
BAS	<b>0.07</b> 10 <sup>9</sup> /l	0 - 0.4	
LYM%	<b>41.7</b> %		
MON%	<b>8.8</b> %		
NEU%	<b>46.5</b> %		
EOS%	<b>2.1</b> %		
BAS%	<b>1.0</b> %		
RBC	<b>9.35</b> 10 <sup>12</sup> /l	5.5 - 8.5	 <b>Alto</b>
HGB	<b>21.8</b> g/dl	12 - 18	 <b>Alto</b>
HCT	<b>62.20</b> %	37 - 55	 <b>Alto</b>
MCV	<b>67</b> fl	60 - 77	
MCH	<b>23.4</b> pg	19.5 - 24.5	
MCHC	<b>35.1</b> g/dl	31 - 39	
RDWc	<b>18.7</b> %	14 - 20	
RDWs	<b>40.6</b> fl		
PLT	<b>378</b> 10 <sup>9</sup> /l	165 - 500	
MPV	<b>9.4</b> fl	3.9 - 11.1	
PCT	<b>0.35</b> %		
PDWc	<b>36.4</b> %		
PDWs	<b>14.0</b> fl		



### CLINICA VETERINARIA MED VET

Carapungo, Galo Plaza Lasso N15-392 y De las Puntas, Quito  
Pichincha, 170103, Ecuador  
+593 95 974 9898, med-vet@outlook.es

Powered by **ZoetisDx**

**Paciente:** DALI - 13575, Perro, SHITZU, 5 Year(s) 7 Month(s), Macho intacto

**Dueño:** AMPARO CALERO

**Veterinario solicitante:** Ninguno

## VETSCAN HM5c - Hematology

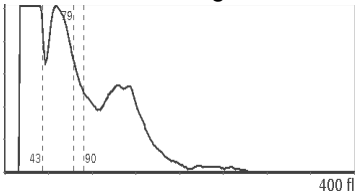
Análisis

22/10/25  
12:30 PM  
HM5

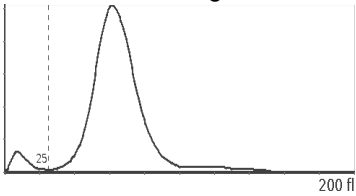
Intervalo de referencia

Gráfico

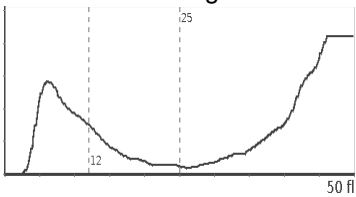
WBC histogram



RBC histogram



PLT histogram



EOS histogram

